Penile Prosthesis Surgery in Patients with Corporal Fibrosis: A State of the Art Review

Juan I. Martínez-Salamanca, MD,* Alexander Mueller, MD,† Ignacio Moncada, MD,‡ Joaquin Carballido, MD, PhD,* and John P. Mulhall, MD§

*Hospital Universitario Puerta de Hierro-Majadahonda, Universidad Autónoma de Madrid, Department of Urology, Madrid, Spain; †University Hospital Zurich, Department of Urology, Zurich, Switzerland; ‡Hospital de la Zarzuela, Department of Urology, Madrid, Spain; §Memorial Sloan-Kettering Cancer Center, New York, USA

DOI: 10.1111/j.1743-6109.2011.02281.x

ABSTRACT

Introduction. Penile prosthesis has become one of the most accepted treatment options in patients who do not respond to conservative medical therapies (oral or intracavernous injections). When penile fibrosis is present, this surgery becomes a real surgical challenge even for a skillful surgeon.

Aim. The aim of this study was to review latest techniques to implant a penile prosthesis in patients with corporal fibrosis.

Methods. We performed a systematic search in the following databases: PubMed, EMBASE, Cochrane, SCOPUS, and Science Citation Index without any date limits for the terms: "penile prosthesis," "penile fibrosis," "impotence," "fibrosis," "cavernotomes," "downsized prosthesis cylinders," "patient satisfaction," "penile graft," and "vascular graft."

Main Outcome Measure. We reported in each technique and series data regarding penile size, complication rate, infection rate, technical pitfalls and details, use of additional surgical tools or implanted material (grafts, etc.), patients' satisfaction, and overall success rate.

Results. When penile corporal fibrosis is present, this surgery becomes a real surgical challenge even for a skillful surgeon. Over the years, multiple surgical approaches have been suggested to facilitate implantation in this difficult situation. Traditional approaches include the resection of scar tissue, performing extensive corporotomies and the eventually use of grafts to cover the corporal gap. Outcomes can be improved combining the use of techniques for scar incision (extensive wide excision, multiple incisions minimizing excision, corporal counter incisions, corporal excavation technique or Shaeer's technique) and cavernotomes and downsized prosthesis. Surgical strategies like upsizing prosthesis, suspensory ligament release or scrotoplasty must be kept in mind to utilize in this special scenario.

Conclusions. Penile prosthesis in a patient with severe corporal fibrosis remains a surgical challenge. There are several techniques and surgical strategies that an implant surgeon should know and manage to minimize complications and improve outcomes. **Martínez-Salamanca JI, Mueller A, Moncada I, Carballido J, and Mulhall JP. Penile prosthesis surgery in patients with corporal fibrosis: A state of the art review. J Sex Med 2011;8: 1880–1889.**

Key Words. Erectile Dysfunction; Penile Prosthesis; Penile Fibrosis; Corporal Fibrosis; Cavernotomes; Downsized Prosthetic Cylinders; Grafting

Introduction

In recent years, important advances have been made in the diagnosis and treatment of erectile dysfunction. Penile prosthesis has become one of the most accepted treatment options in patients who do not respond to conservative medical therapies (oral or intracavernous injections). When penile fibrosis is present, this surgery becomes a real surgical challenge even for a skillful surgeon [1].

There are a variety of causes of corporal fibrosis:

- The worst and most severe fibrosis occurs after removal of an infected implant. In these

patients, the fibrosis causes significant penile shortening [2,3]
- Priapism [4–7]
- Penile trauma [8]
- Peyronie's disease [6,9,10]
- Use of pharmacologic erection program [3,11]

Penile fibrosis after priapism (usually distal) and infection (more common proximal) is usually extensive and dense. In the presence of fibrosis in the non-implant patient, venous leak will be present and will preclude men having spontaneous erections and will allow only a minority to respond to phosphodiesterase type 5 inhibitors [12] is the best option for these patients.

When secondary implant surgery is indicated, the surgeon needs to be very cautious in counseling patients and partners. The penile shortening that usually occurs even when the implant is successful, may be an important issue to the patient, especially in patients with implant removal for a previous infection rather than priapism ones. Knoll suggests that no promises, guarantees, or unrealistic expectations should be given to them. An implant failure should not be considered a surgeon's error [13].

Over the years, multiple surgical approaches have been suggested to facilitate implantation in this difficult situation. Traditional approaches include the resection of scar tissue, performing extensive corporotomies, and the use, eventually, of grafts to cover the corporal gap. In 1995, Wilson et al., suggested that the combination of an adequate incision, the use of cavernotomes (Figures 1 and 2), and a downsized implant could be another possible option. Recently, some groups have described new techniques to achieve better scar resection [14–16]. This manuscript is a review of these techniques and their results.

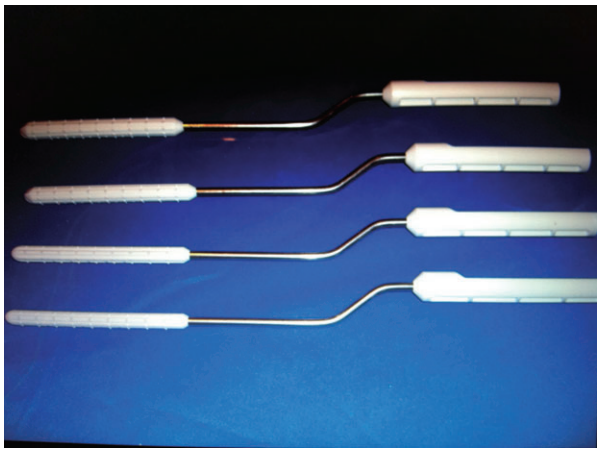

Figure 1 Carrión-Rosello Cavernotomes.



Figure 2 Uramix or Mooreville Cavernotomes.

Materials and Methods

We performed a systematic search in the following databases: PubMed, EMBASE, Cochrane, SCOPUS, and Science Citation Index without any date limits for the terms: "penile prosthesis," "penile fibrosis," "impotence," "fibrosis," "cavernotomes," "downsized prosthesis cylinders," "patient satisfaction," "penile graft," and "vascular graft." We analyzed the most representative series and description of techniques.

Different Surgical Techniques and Results

Scar Excision

Implantation of a penile prosthesis into scarred corpora almost always presents a surgical challenge. Conventionally, penile fibrosis has been treated surgically by extensive excision of scar tissue. We describe several available techniques [13,17–20].

Extensive Wide Excision of the Scar Tissue

This should be considered the classic approach. Many authors have reported their experience with this technique.

The technique consists of dissecting the fibrotic corporal tissue carefully from the surrounding relatively normal tunica albuginea by extending the penoscrotal incision and the corporotomy distally as far as is feasible. The early complication rate is about 30% and the incidence of later complications is 50–65%. These include infection

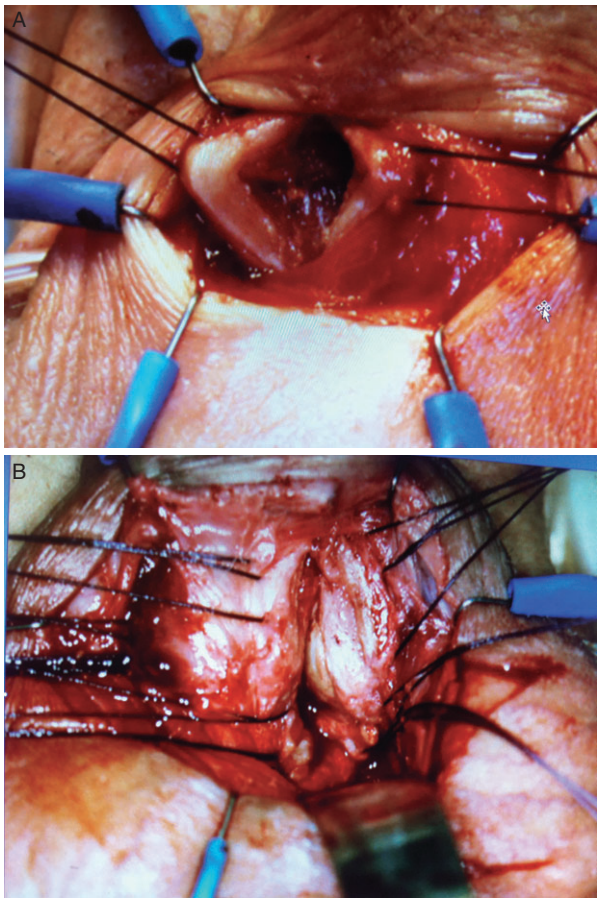

Figure 3 (A) Corporotomy with normal cavernous tissue. (B) Corporotomy showing intense corporeal fibrosis.

(18–30%), penile angulation (6%), pain (6%), reoperation (30–50%), and malfunction of the device (6–12%) [13,17–21].

Wilson et al. reported their experience from 1987–1991 in 20 cases of salvage penile prosthesis implantation via standard infrapubic or penoscrotal approach using extensive corporotomies, fibrotic tissue resection and frequent Gore-Tex grafting. The 1-year prosthesis survival was only 50%; complications were urethral laceration (three cases), inadequate proximal dilation (four cases), and prosthetic infection (three cases) [22].

Multiple Incisions and Minimal Scar Tissue Excision

This was first published in 1996 and then in 1999 by Dhabuwala et al. [23,24]. The author performs a minimal excision (small corporotomy 2 cm) (Figure 3A) of scar tissue (Figure 3B) followed by dilation of the corpus cavernosum under vision (starting with blunt-tipped Metzenbaum scissors (Figure 4) and then 7- or 11-gauge Hegar dilators and/or Dilamezinsert), and the insertion of the penile implant (Figure 5). If dilation of the distal corpora was difficult, an additional subcoronal incision is made and the distal fibrotic area is dilated. When it was difficult to close the defect in the tunica albuginea after insertion of the prosthe-

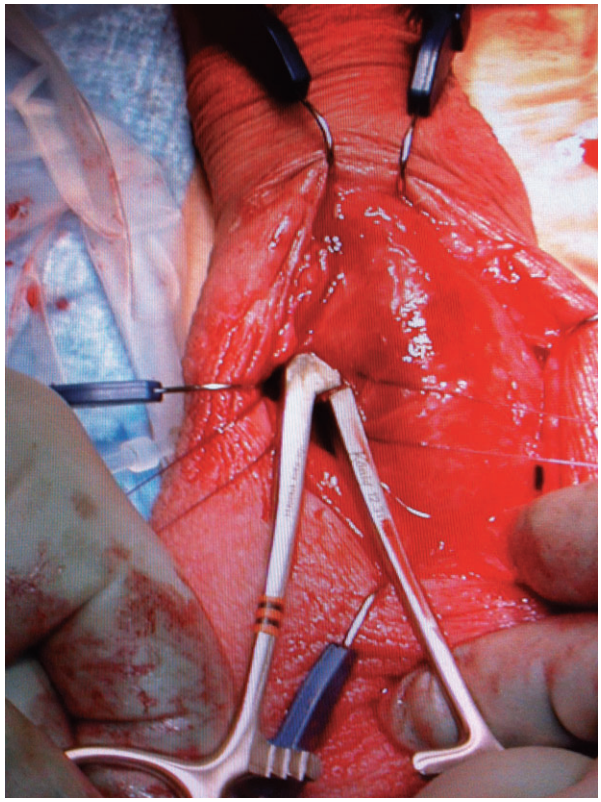

Figure 4 Metzenbaum scissors insertion to develop space inside scar tissue.

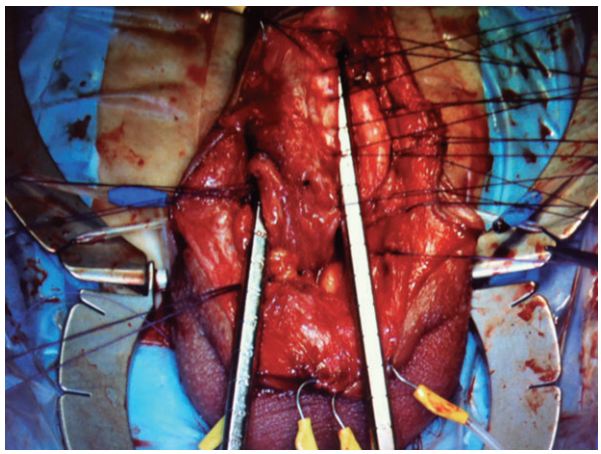

Figure 5 Intense fibrosis, dilators place into both cavernous bodies.

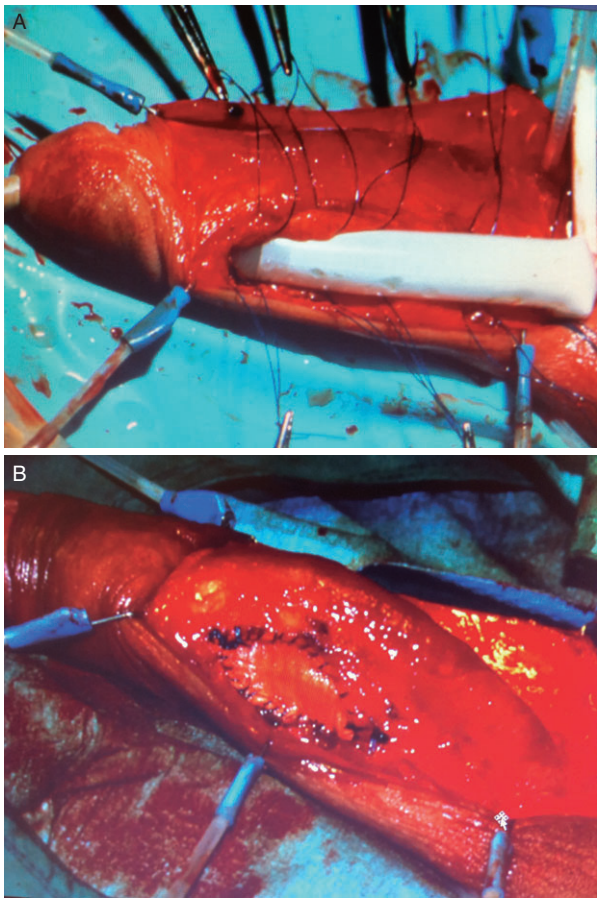

Figure 6 (A) and (B) Extended corporotomy and polutetrafluoroethylene path to close it.

sis, they used a polutetrafluoroethylene (PTFE) graft (Figure 6A, B). They did not use any kind of cavertomes and they were able to achieve successful dilation and implantation. They reported their experience in 34 patients, 2.9% had intraoperative complications and another 2.9% postoperative complications. None of the patients developed infection after surgery. They have not reported data about penile length or patient/partner satisfaction.

Corporal Counter Incisions

Published by Ghanem et al., in 2000 [25], the technique has several steps:

- Step 1: A subtunical tract is created and dilated using Metzembaum scissors followed by small-caliber Hegar dilators and finally the dilamezinsert instrument.
- Step 2: A subcoronal incision is made, and the corpora is incised in the manner mentioned above. Lateral subtunical tracts are then established using scissors and fine Hegars dilator but this time from distal to proximal.

The technique only allows implanting malleable rods and might not be suitable for implanting inflatable cylinders based on the space limitations. The authors have reported that sometimes, the closure of the corporotomy is difficult but they never use grafts. If the defect is small (less than 4 cm) it is covered with Buck fascia.

After treating 17 patients, they report only one intra operative complication (crural perforation) and no infection or other postoperative complications.

Corporal Excavation

Fishman briefly described the corporeal excavation technique in 1989, without reported results [26]. Then, it was well reported by Montague and Angermeier in 2006 [14]. The technique begins with a long corporotomy. Metzembaum scissors are used to establish a plane of dissection between the undersurface of the tunica and the fibrotic area. The fibrotic core is transected distally proximal to the glans and proximally into the crural area. This long segment of scar is completely excised. The authors suggest placing a downsized inflatable prosthesis (CXM cylinders or Titan Narrow Base).

The authors reported on a total of nine patients with a mean follow-up of 44 months. The only intra- or postoperative complications reported was prosthesis replacement because of cylinder failure after 46 months of use. No data about penile length or satisfaction were provided.

Shaeer's Technique

In 2007, Shaeer described this unique and innovative technique. They propose a *trans*-corporeal resection using optical corporotomy in order to excavate the fibrotic tissue under direct vision (Penoscopy). The instruments and technique are the same as for endoscopic urethrotomy and transurethral resection. An optical corporotomy is performed where the corpora are incised and after a wide enough channel is created, they use a resectoscope (with loop) to excise all the fibrotic tissue under direct vision. They report that the introduction of the instrument inside the corpora is not difficult. A 26-French sheath (8.6 mm in diameter) can be easily introduced through a 1 cm corporotomy. After six cases, no intraoperative complications or infection were recorded. The patients and partner satisfaction based on the length (2 cm average of increase) and girth (increased of 40%)

were high. Average operative time was 90 minutes. The postoperative pain was tolerable [16,27].

The same group described another technique following the same principals but using ultrasound (linear 7.5 MHz probed) to monitor and guide penoscopic excavation (rather than using loop-resectoscope) toward the tip of the corpora using a central venous pressure catheter size 14G. Authors argued that guidance penoscopy decrease the possibility of perforation at the tips of the corpora and crura. Also, these two approaches (penoscopy and ultrasound guidance) allow combining both techniques [15,28].

They report a total of 12 patients, dilated up to 13.5 in 10 cases, and up to 14 in two. Satisfactory implantation of 13 cm prosthesis was performed in all cases without any significant complication. [15,28]

Grafting (Materials)

Many of the authors using the technique of fibrotic excision often utilize a graft because closure of the corpora is difficult. Several strategies and graft materials have been proposed. One strategy suggests leaving the defect open and closing the overlying fascia and skin over the implant. This technique has several problems, including a greater risk of infection, migration and deformity during inflation, malfunction, or erosion [29,30].

Grafts have become popular for this reason. There are several grafts reported: heterologous synthetic (Gore-Tex™ [13,31], Dacron, Prolene) and biological (human cadaveric fascia, porcine tissue, dermis, pericardium [32–34], and small intestinal sub mucosa [35,36]).

Harvested autologous grafts represent another interesting option, including rectus fascia [37], fascia lata, dermis, saphenous vein, temporalis fascia and tunica albuginea [38–40]. Synthetic grafts differ from native tunica in tensile strength and expandability [38]. These characteristics limit the full expansion potential of the cylinders [41,42]. The advantage of autologous materials includes being non-immunogenic and having decreased likelihood of becoming infected [33].

The major adverse factor in using vascular graft material with a penile implant is the risk of infection. Knoll et al. reported a 30% infection rate in 57 patients with cavernous fibrosis who received prosthesis with PTFE grafting and a 5% infection rate in a similar group of 20 patients who received downsized inflatable cylinders to obviate the need of grafting [43]. Similarly, Jordan et al. reported three infections in seven patients with PTFE grafts on implants for phallic reconstructions and the implants were removed in all three patients [44]. Conversely, no infections were reported in other series of grafting of Mulcahy [45], Levine et al. [46], Seftel et al. [47], and Herschorn [31].

Pathak et al. reported their experience using rectus fascia grafts for corporeal reconstruction during penile implantation. They performed the technique in a total of 15 patients with severe fibrosis of the corpora or tunica that underwent penile prosthesis surgery. After a mean follow-up of 18 months all the implants were functioning correctly with no evidence of complications including infection. The disadvantage of this approach is that there is a need for another incision to harvest the autologous graft.

Palese and Burnett [33], described the technique using pericardium allograft (*Tutoplast*™, Tutogen Medical, Inc., Alachua, FL, USA) in four patients. No complications were reported [33].

Use of Cavernotomes

In 1995 Wilson et al., introduced the concept of drilling into a fibrous cavernous body instead of resecting the scar tissue (Figure 3A, B). For this purpose the use of cavernotomes is indispensable. Basically there are two available. The first one is the *Carrion-Rosello* cavernotome [48] (Figure 1). The original was made from stainless steel but now a single use polycarbonate version (sized from 9 mm to 12 mm) is in the market.

Technique: The instrument works like a wood rasp with teeth projecting from sides of the device. The configuration as a bayonet allows the surgeon to advance and cut the fibrosis inside the corpora. Consecutive movements of pronation and supination of the hand facilitate a tunnel creation (Figure 7 and 8). The teeth allow the cavernotome to "walk" forward through the fibrosis and seem to protect against a sudden forward uncontrolled movement that can cause an inadvertent urethral laceration [2].

Wilson et al. reported, in 1995, their results with 32 salvage inflatable penile prosthesis using this technique. Using a transverse incision (Figure 9A, B); cavernotomes and downsized prosthesis (AMS 700 CXR), [49] the 1-year prosthesis survival increased to 87% and complications were significantly reduced with just two cases of inadequate proximal dilation and two cases of prosthesis infection. Urethral perforation was not observed and they did not use any grafting [22].

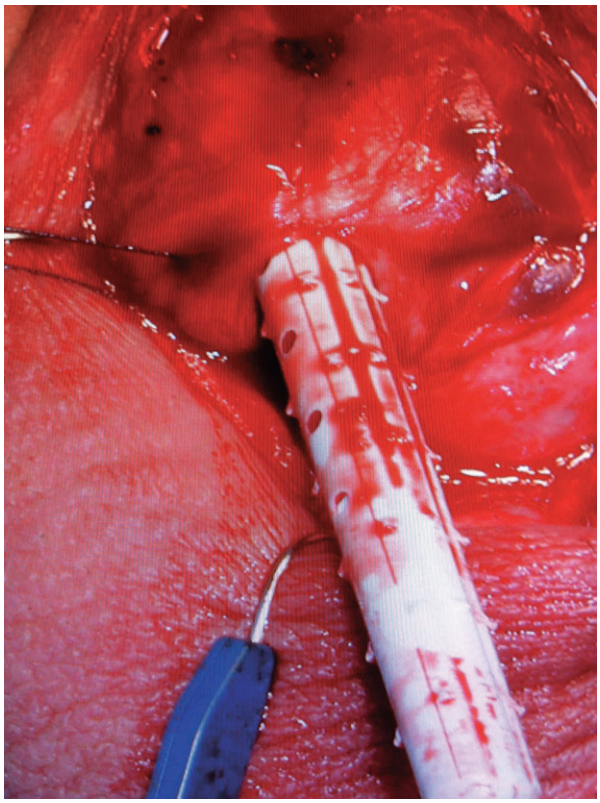

Figure 7 Rosello Cavernotome drilling the corpora.

There is another type of cavernotomes called "*Uramix or Mooreville*" (Figure 2), cavernotomes [50]. It comes in a set of five cavernotomes made of stainless steel, sized from 6–13 mm. and 23 cm length.

Technique: The blade arises from a beveled surface that allows 1 mm. shavings of tissue to be resected. Cutting can be done in a longitudinal, up and down movement, or in a "drilling" rotational movement. The design and oscillating advancement promote safe dilation without perforation [50] (Figure 8).

Both of the cavernotomes are very helpful and the final effect on the cavernous body will be similar. The thickness of the tunica is considerable and the configuration of either of the cavernotomes does not let itself to cut through it [2]. Wilson recommends the *Uramix* cavernotome for distal and *Rosello* for proximal dilation (Figures 1 and 2). The *Otis urethrotome* can also be used for this purpose. Mulcahy reported the use of it in this fashion [51]. Initially a channel is developed inside the corpora with scissors. Once this is done, the urethrotome is used for sharply incising, keeping away from the urethra.

Use of Downsized Prostheses

Knoll described this concept in 1995. He proposed using a downsized inflatable prosthesis plus Gore-Tex graft when the dilation was not possible [52].

The use of a downsized prosthesis cylinder allowed secondary implantation since it does not require dilating a space as large as is necessary for insertion of a standard cylinder. There are two types of prosthesis devices available. The standard *AMS CXR* and the *Mentor Titan NB* ("*Narrow Base*").

The new AMS 700CX series cylinder with the Momentary Squeeze pump only needs dilatation to 10 mm proximally for insertion while Coloplast Titan needs al least 12 mm. Furlow inserter only requires dilatation to 9 mm. AMS 700 CXR and Coloplast Titan NB require dilatation to 9 mm and 10 mm, respectively, and addition of rear tip extenders (RTEs) does not increase the diameter. It is important to note that the base of the CXR and the NB have an additional 3 cm of non-inflatable to facilitate insertion in these difficult cases. The cylinders are 15–18 mm width where the tubing exits and that is why the downsized cylinders are easier to use. It is completely impos-

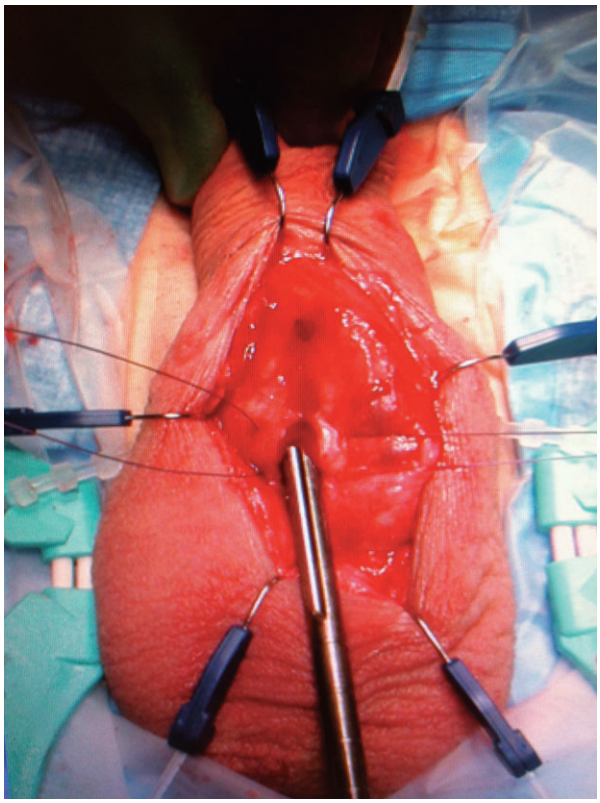

Figure 8 Uramix/Mooreville insertion.

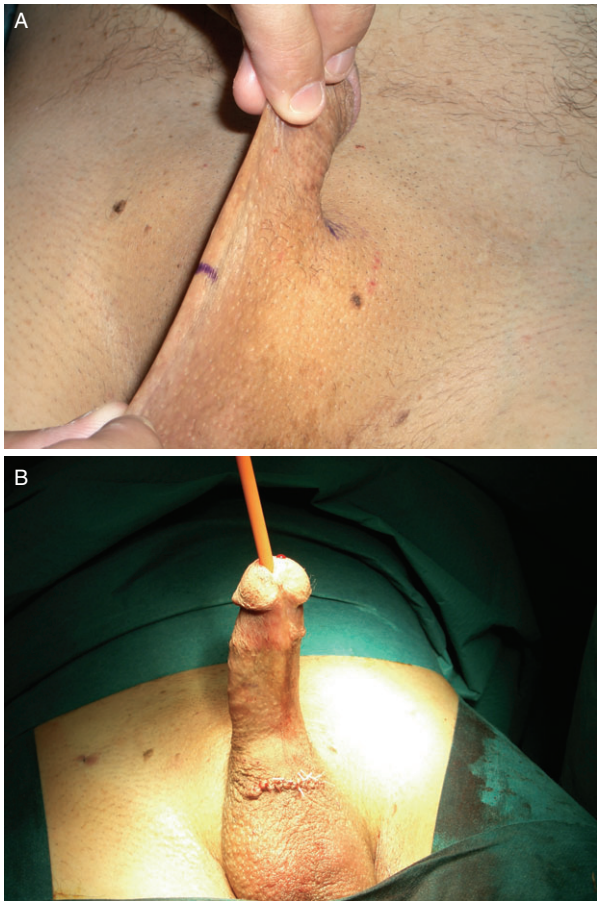

Figure 9 (A) and (B) Scrotoplasty (before and after).

sible to insert the tube exit portion of any cylinder in stenotic fibrotic corpora. The standard device cylinders require proximal dilation to at least 13 mm.

Please note that AMS 700CX and Coloplast Titan have locking RTEs so the units can not be left behind if the cylinder has to be removed because of crossover, etc.

Wilson recommends liberal use of rear tip extenders to avoid running the input tubing along the cylinders [2]. He suggested that the downsized cylinders have smaller inflatable chambers, which obviate the use of grafting material to close the corpora [2].

The cavernotome can drill a channel though the fibrotic corpora without extending the corporotomy and avoiding the graft, but surgeon needs to be very careful because around 50% of the time proximal corporal perforations are seen using cavernotomes due to you are drilling into dense tissue without the usual landmarks (Figure 7).

Knoll reported his experience in a total of 20 patients without a graft; they had one supersonic transporter (SST) deformity and one infection requiring device removal as postoperative complications.

Erection rigidity with downsized implant is good in the majority of cases [52]. The major complaint of these patients is the shortening in penile length after reimplantation. Typically the downsized cylinder is 4–6 cm shorter than the original implant [52].

Size Matters: Strategies to Minimize It

Even when a surgeon considers the operation a technical success, the patient in these difficult cases is disappointed and desires the same penile length as with the original implant. Replacement of the elastic spongy erectile tissue with fibrosis manifests itself clinically by shortening of the penis [53]. This contracted scar tissue leads to a shorter erection by up to 6 cm [54]. Several strategies have been proposed in order to fix this problem:

Upsizing after Reimplantation

Proposed in 2006 by Wilson et al., the idea is to use the downsized inflatable penile prosthesis cylinders as tissue expander in patients with corporal fibrosis. They reported a total of 37 patients with previous reimplantation into scarred bodies [53]. In no case was it possible to dilate to 12 mm. in order to insert a standard prosthesis. Patients were advised to inflate their implants for up to 3 hours daily. After several months the intracorporal stretching occurred. The objective was to replace the smaller-width cylinders with a standard cylinder. The original implants had length measurement 2–7 cm less than the corporal measurements at the time of original implantation. The final cylinder length represents a 12.4% decrease in the mean length (2.3 cm) from the original implant [53].

Release of the Suspensory Ligament (Figure 10A, B)

This was first proposed by Knoll et al. in 1996 along a suprapubic Y-V flap advancement procedure and a lower abdominal tissue debulking to improve the functional length. They reported that the patients gain an additional 3.5–6.5 cm in functional length. All patients had a functional device after a mean follow-up of 12 months. No complications related with the procedure were recorded [55].

Recently, Borges et al., reported their experience adding suspensory ligament release to the standard penile prosthesis implantation [56]. They recommended that the ligament be incised when

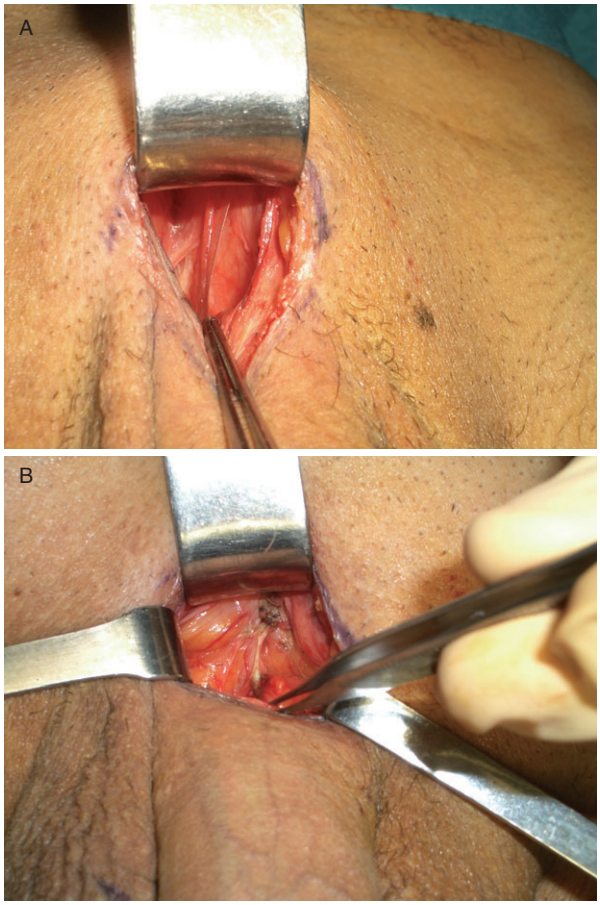

Figure 10 (A) and (B) Release of the suspensory ligament (before and after).

the device is inflated because an inflated device allows the penis to be easily pressed down. This maneuver is useful to identify the corpora structure and the neurovascular bundle, avoiding possible damage to them. In 303 procedures, the erect measurement increased an average of 1.73 cm (1.1–2.2 cm), from 10.7 cm to 12.4 cm, after suspensory ligament incision [56].

Scrotoplasty (Figure 9A, B)

Many of these patients have a webbed penoscrotal union caused by multiple surgeries and penile shrinkage. The cosmetic appearance can be improved by closing the transverse incision in a vertical fashion, sometimes doing a partial scar skin excision may improve the final appearance. [2,53]. It is important to point out how this simple and easy procedure improves the cosmetic appearance of the erect and flaccid penis.

Patient Satisfaction after Reimplantation

Patient satisfaction is a complex issue that is related to the expectations that are formulated in the preoperative period [57]. Several studies have shown that patients who undergo prosthesis implant into fibrotic corporal bodies, have significantly less device efficacy and satisfaction [53,58].

While the loss of penile length remains the most likely cause of diminished satisfaction with prostheses re-implantation, it does not fully explain why the device efficacy measured by the Erectile Function (EF) domain is significantly lower in this group of patients [58].

Mulcahy et al. suggested that there might be diminished penile sensitivity, as well as ejaculatory problems in patients with penile fibrosis [59]. Altered sensitivity may directly impact on the EF domain and the indirect impact of ejaculatory disturbances are unknown [58].

Conclusions

After an extensive review of the most important article published in this issue, we could say that secondary implantation of a penile prosthesis in a patient with severe corporal fibrosis remains a surgical challenge. There are several techniques and surgical strategies reviewed in this paper that an implant surgeon should know and manage to minimize complications and improve outcomes.

Acknowledgments

We would like to thank Dr. Steven Wilson for his support, knowledge, and unflagging collaboration.

Corresponding Author: Juan I. Martinez-Salamanca, MD, Department of Urology, Hospital Universitario Puerta de Hierro-Majadahonda, c/ Manuel de Falla n°1, Madrid, 28222, Spain. Tel: 34620255030; Fax: 34915348983; E-mail: jims09@me.com; msalamanca99@hotmail.com

Conflict of Interest: None.

Statement of Authorship

Category 1

(a) **Conception and Design**
Juan I. Martinez-Salamanca; Ignacio Moncada; John Mulhall

(b) **Acquisition of Data**
Juan I. Martinez-Salamanca; Alex Müller

(c) **Analysis and Interpretation of Data**
Juan I. Martinez-Salamanca; Joaquin Carballido

Category 2

(a) **Drafting the Article**
Juan I. Martinez-Salamanca

(b) Revising It for Intellectual Content
Juan I. Martinez-Salamanca; Ignacio Moncada; John Mulhall; Alex Müller; Joaquin Carballido

Category 3

(a) Final Approval of the Completed Article
Juan I. Martinez-Salamanca; Ignacio Moncada; John Mulhall; Alex Müller; Joaquin Carballido

References

1 Hellstrom WJ, Montague DK, Moncada I, Carson C, Minhas S, Faria G, Krishnamurti S. Implants, mechanical devices, and vascular surgery for erectile dysfunction. J Sex Med 2010;7:501–23.
2 Wilson SK. Reimplantation of inflatable penile prosthesis into scarred corporeal bodies. Int J Impot Res 2003;15(suppl 5):S125–8.
3 Gasser TC, Larsen EH, Bruskewitz RG. Penile prosthesis reimplantation. J Urol 1987;137:46–7.
4 Stember DS, Mulhall JP. Ischemic priapism and implant surgery with sharp corporal fibrosis excision. J Sex Med 2010;7:1987–90.
5 Bertram RA, Carson CC 3rd, Webster GD. Implantation of penile prostheses in patients impotent after priapism. Urology 1985;26:325–7.
6 Devine CJ Jr, Horton CE. Bent penis. Semin Urol 1987;5:251–61.
7 Macaluso JN Jr, Sullivan JW. Priapism: Review of 34 cases. Urology 1985;26:233–6.
8 Orvis BR, McAninch JW. Penile rupture. Urol Clin North Am 1989;16:369–75.
9 Furlow WL, Swenson HE Jr, Lee RE. Peyronie's disease: A study of its natural history and treatment with orthovoltage radiotherapy. J Urol 1975;114:69–71.
10 Levine LA, Benson J, Hoover C. Inflatable penile prosthesis placement in men with Peyronie's disease and drug-resistant erectile dysfunction: A single-center study. J Sex Med 2010;7:3775–83.
11 Larsen EH, Gasser TC, Bruskewitz RC. Fibrosis of corpus cavernosum after intracavernous injection of phentolamine/papaverine. J Urol 1987;137:292–3.
12 Jordan GH, Angermeier KW. Preoperative evaluation of erectile function with dynamic infusion cavernosometry/cavernosography in patients undergoing surgery for Peyronie's disease: Correlation with postoperative results. J Urol 1993;150:1138–42.
13 Knoll LLD. Use of penile prosthetic implants in patients with penile fibrosis. Urol Clin North Am 1995;22:857–63.
14 Montague DK, Angermeier KW. Corporeal excavation: New technique for penile prosthesis implantation in men with severe corporeal fibrosis. Urology 2006;67:1072–5.
15 Shaeer O. Implantation of penile prosthesis in cases of corporeal fibrosis: Modified Shaeer's excavation technique. J Sex Med 2008;5:2470–6.
16 Shaeer O. Penoscopy: Optical corporotomy and resection for prosthesis implantation in cases of penile fibrosis, Shaeer's technique. J Sex Med 2007;4:1214–7.
17 Jarow JP. Risk factors for penile prosthetic infection. J Urol 1996;156:402–4.
18 Knoll LD, Furlow WL. Corporeal reconstruction and prosthetic implantation for impotence associated with non-dilatable corporeal cavernosal fibrosis. Acta Urol Belg 1992;60:15–25.
19 Boyd S, Martin F. Simultaneus ultrex penile prosthesis re-implantation and Gore-Tex grafting corporoplasty functional outcome of a surgical challenge. J Urol 1995;153.
20 Goldstein I, Nehra A, Wener M. Technique and follow-up of sharp corporal tissue excision procedure for prosthesis implantation with bilateral severe diffuse corporal fibrosis. J Urol 1995;153.
21 Fishman IJ, Scott FB, Light JK. Experience with inflatable penile prosthesis. Urology 1984;23:86.
22 Wilson SK, Terry T, Delk JR. Improved implant survival in patients with severe corporal fibrosis: A new technique without necessity of grafing. J Urol 1995;153.
23 Rajpurkar AA, Li HH, Dhabuwala CCB. Penile implant success in patients with corporal fibrosis using multiple incisions and minimal scar tissue excision. Urology 1999;54:145–7.
24 George VVK, Shah GGS, Mills RR, Dhabuwala CB. The management of extensive penile fibrosis: A new technique of minimal scar-tissue excision. Br J Urol 1996;77:282–4.
25 Ghanem HH, Ghazy SS, El-Meliegy AA. Corporeal counter incisions: A simplified approach to penile prosthesis implantation in fibrotic cases. Int J Impot Res 2000;12:153–6.
26 Fishman IJ. Corporeal reconstruction procedures for complicated penile implants. Urol Clin North Am 1989;16:73–90.
27 Shaeer OO, Shaeer AA. Corporoscopic excavation of the fibrosed corpora cavernosa for penile prosethesis implantation: Optical corporotomy and trans-corporeal resection, Shaeer's technique. J Sex Med 2007;4:218–25.
28 Shaeer O. Penile prosthesis implantation in cases of fibrosis: Ultrasound-guided cavernotomy and sheathed trochar excavation. J Sex Med 2007;4:809–14.
29 Carson CC, Noh CH. Distal penile prosthesis extrusion: Treatment with distal corporoplasty or Gortex windsock reinforcement. Int J Impot Res 2002;14:81–4.
30 Diokno AC. Asymmetric inflation of the penile cylinders: Etiology and management. J Urol 1983;129:1127–30.
31 Herschorn S, Ordorica RC. Penile prosthesis insertion with corporeal reconstruction with synthetic vascular graft material. J Urol 1995;154:80–4.
32 Lopes EJ, Kuwano AY, Guimaraes AN, Flores JP, Jacobino MA. Corporoplasty using bovine pericardium grafts in complex penile prosthesis implantation surgery. Int Braz J Urol 2009;35:49–53.
33 Palese MA, Burnett AL. Corporoplasty using pericardium allograft (tutoplast) with complex penile prosthesis surgery. Urology 2001;58:1049–52.
34 Lopes EJ, Santos TC, Jacobino M. Bovine pericardium in penile prosthesis reimplantation. Int Braz J Urol 2007;33:74–6.
35 Knoll LD. Use of porcine small intestinal submucosal graft in the surgical management of Peyronie's disease. Urology 2001;57:753–7.
36 Monga M, Cosgrove D, Zupkas P, Jain A, Kasyan A, Wilkes N, Rajasekaran M. Small intestinal submucosa as a tunica albuginea graft material. J Urol 2002;168:1215–21.
37 Tran VQ, Lesser TF, Kim DH, Aboseif SR. Penile corporeal reconstruction during difficult placement of a penile prosthesis. Adv Urol 2008;2008:370947. Epub, 370947 (2008).
38 Pathak AS, Chang JH, Parekh AR, Aboseif SR. Use of rectus fascia graft for corporeal reconstruction during placement of penile implant. Urology 2005;65:1198–201.
39 Kim ED, McVary KT. Long-term followup of treatment of Peyronie's disease with plaque incision, carbon dioxide laser plaque ablation and placement of a deep dorsal vein patch graft. J Urol 1995;153:1843–6.
40 Melman A, Holland TF. Evaluation of the dermal graft inlay technique for the surgical treatment of Peyronie's disease. J Urol 1978;120:421–2.
41 Bitsch M, Kromann-Andersen B, Schou J, Sjøntoft E. The elasticity and the tensile strength of tunica albuginea of the corpora cavernosa. J Urol 1990;143:642–5.

42 Gelbard MK, Hayden B. Expanding contractures of the tunica albuginea due to Peyronie's disease with temporalis fascia free grafts. J Urol 1991;145:772–6.
43 Knoll LD, Furlow WL, Benson RC, Bilhartz DL. Management of nondilatable cavernous fibrosis with the use of a downsized inflatable penile prosthesis. J Urol 1995;153:366–7.
44 Jordan GH, Alter GJ, Gilbert DA, Horton CE, Devine CJ Jr. Penile prosthesis implantation in total phaloplasty. J Urol 1994;152:410–4.
45 Mulcahy JJ. A technique of maintaining penile prosthesis position to prevent proximal migration. J Urol 1987;137:294–6.
46 Levine LA, Zachary LS, Gottlieb LJ. Prosthesis placement after total phallic reconstruction. J Urol 1993;149:593–8.
47 Seftel AD, Oates RD, Goldstein I. Use of a polytetrafluoroethylene tube graft as a circumferential neotunica during placement of a penile prosthesis. J Urol 1992;148:1531–3.
48 Rosello Barbara M, Carrion HM. Cavernotomy. Arch Esp Urol 1991;44:185.
49 Summerton DJ, Terry TR, Delk JR, Wilson SK. Reimplantation of inflatable penile prostheses (IPP) into scarred corporeal bodies facilitated by the new AMS 700CXR cylinders. BJU Int 2005;95(5 suppl):102.
50 Mooreville M, Adrian S, Delk JR 2nd, Wilson SK. Implantation of inflatable penile prosthesis in patients with severe corporeal fibrosis: Introduction of a new penile cavernotome. J Urol 1999;162:2054–7.
51 Mulcahy JJ. Editorial comment. J Urol 1999;162:2057.
52 Wilson SK, Delk JR 2nd. Inflatable penile implant infection: Predisposing factors and treatment suggestions. J Urol 1995;153:659–61.
53 Wilson SK, Delk JR, Mulcahy JJ, Cleves M, Salem EA. Upsizing of inflatable penile implant cylinders in patients with corporal fibrosis. J Sex Med 2006;3:736–42.
54 Mulcahy JJ. Long-term experience with salvage of infected penile implants. J Urol 2000;163:481–2.
55 Knoll LD, Fisher J, Benson RC Jr, Bilhartz DL, Minich PJ, Furlow WL. Treatment of penile fibrosis with prosthetic implantation and flap advancement with tissue debulking. J Urol 1996;156:394–7.
56 Borges F, Hakim L, Kline C. Surgical technique to maintain penile length after insertion of an inflatable penile prosthesis via infrapubic approach. J Sex Med 2006;3:550–3.
57 Mulhall JP, Ahmed A, Branch J, Parker M. Serial assessment of efficacy and satisfaction profiles following penile prosthesis surgery. J Urol 2003;169:1429–33.
58 Kava BR, Yang Y, Soloway CT. Efficacy and patient satisfaction associated with penile prosthesis revision surgery. J Sex Med 2006;4:509–18.
59 Mulcahy JJ. Surgical management of penile prosthesis complications. Int J Impot Res 2000;12(4 suppl):S108–11.